

## *Tooth in Nasal Cavity of Non-traumatic Etiology: Uncommon Affection*

**Henrique Fernandes de Oliveira\***, **Marcelo Braz Vieira\*\***, **Wady Miguel Santos Bubaten\*\*\***,  
**Caio Athayde Neves\*\*\*\***, **Giovanni Paolo Seronni\*\*\*\*\***, **Mário Orlando Dossi\*\*\*\*\***.

\* Graduation in Medicine/UFMG. Resident Doctor in Otorhinolaryngology.

\*\* Otorhinolaryngologist. Otorhinolaryngologist for the Armed Forces Hospital.

\*\*\* Otorhinolaryngologist. Otorhinolaryngologist.

\*\*\*\* Graduation in Medicine/UnB. Resident Doctor in Otorhinolaryngology.

\*\*\*\*\* Graduation in Medicine. Resident Doctor in Otorhinolaryngology.

\*\*\*\*\* Graduation in Medicine/UFMS. Resident Doctor in Otorhinolaryngology.

Institution: Hospital das Forças Armadas Serviço de Otorrinolaringologia e Cirurgia de Cabeça e Pescoço.  
Brasília / DF – Brazil.

Mail address: Henrique Fernandes de Oliveira – Hospital das Forças Armadas – Avenida Contorno do Bosque s/n Clínica de Otorrino – Cruzeiro Novo  
– Brasília / DF – Brazil – Zip code: 70658-900 – Telephone: (+55 61) 3966-2350 / 8185-6177 – Fax: (+55 61) 3233-0812 – E-mail: hfdoliveira@yahoo.com.br

Article received on December 08 2007. Accepted on July 31 2008.

### SUMMARY

- Introduction:** The presence of ectopic supernumerary tooth is not an uncommon fact, and the estimate is that 1% of the population is affected. However, a tooth in nasal cavity is a rare event, independently of the etiology.
- Objective:** To report a case of a tooth in nasal cavity whose etiology is neither traumatic and nor iatrogenic. Case report: The young patient presented with a radiopaque image in nasal cavity during dental propedeutics. Upon otorhinolaryngological exams, a tooth was identified, in spite of no existence of any trauma. Surgical treatment was carried out without complications.
- Final Comments:** The presence of tooth in nasal cavity, in spite of being uncommon, must be given special attention. The dangerous triangle of the face is a potential place of complications, therefore, the approach must be surgical even in asymptomatic patients.
- Keywords:** nasal cavity, surgery, tooth.

## INTRODUCTION

The presence of supernumerary or ectopic tooth ins not uncommon, and it's estimated to occur in 1% of the general population (1), specially in children (2) and involving the first dentition (3). However, a tooth in nasal cavity is an uncommon event, no matter the etiology. It may be symptomatic or not and the diagnosis is clinical and radiological (1). The treatment must aim at the dental extraction, whether for the symptoms recurrences and the location of the face dangerous triangle, a potential region of complications (1).

This report addresses a young patient with a tooth in the nasal cavity with the objective of emphasizing the fact the etiology is not traumatic nor iatrogenic and such clinical presentation is still rare. He was approached with adequate propedeutics, through video-endoscopic and tomographic images that enable a safe surgical planning (3).

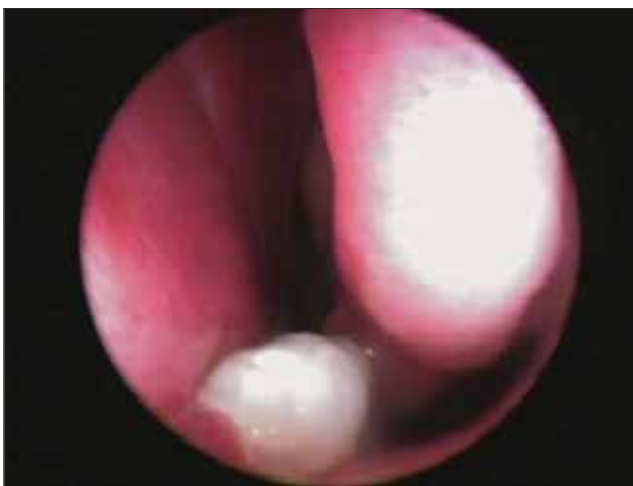The report also evidences the need for a good relationship between otorhinolaryngology and dentology for the benefit of the patient.

## CASE REPORT

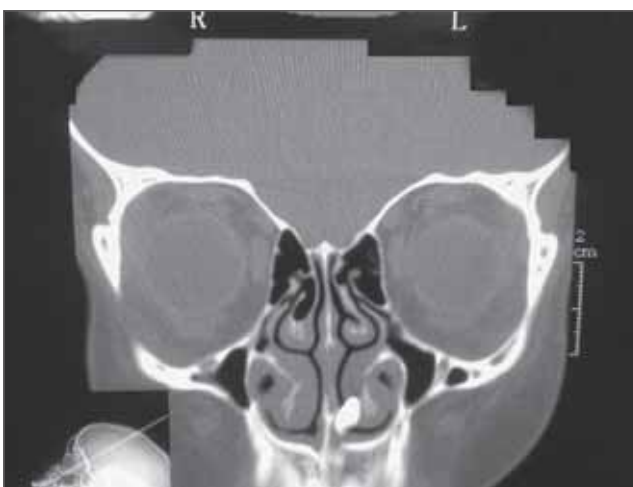The patient G.S.C, male, 12 years old, white was in dental treatment when, upon radiographic propedeutics, a radiopaque image was viewed in the nasal region. The patient was sent to otorhinolaryngology service for evaluation. Upon clinical exam, a mass on the floor of the left nasal cavity was viewed, which was better characterized by nasal video-endoscopy (Picture 1). The patient, asymptomatic, denied any previous trauma involving the craniofacial region. Computed tomography was requested of the paranasal sinuses (Pictures 2 and 3), which enabled the confirmation of the existence of a mass compatible with the dental osseous tissue in the left nasal cavity. The patient was submitted to surgical treatment under general anesthesia, by using rigid endoscopy of 30° during the procedure. Local infiltration with lidocaine and adrenaline was carried out in the concentration of 1:80.000. The tooth extraction (Picture 4) was carried out by using an instrument to unglue it between the limits of the osseous mass and the nasal floor, and no strong resistance was found for such removal. There was no abnormalities during the procedure.

## DISCUSSION

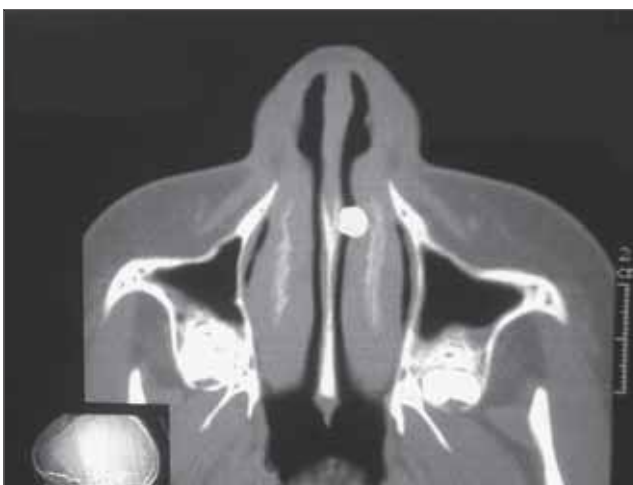
Dental injuries reach 1.7% of the children per year (2). Among the causes, the traumatic intrusion, a common form of incidence in the primary dentition, reaches 11% of girls and 15% of boys between 0 and 12 year with a peak



**Picture 1.** Nasal video-endoscopy confirming a mass on the left nasal cavity floor.



**Picture 2.** Computed tomography - coronal cut confirming radiopaque image in the left nasal cavity.



**Picture 3.** Computed tomography - axial cut confirming radiopaque image in the left nasal cavity.

between 1 and 3 years (2). The central primary incisors are involved in 80.8% of the cases. In the other hand, the traumatic etiology in permanent dentition is rare (3).

In addition to the trauma, other possible etiologies for dental intrusion in nasal cavity are: rhinogenic maxillary infection, dental infection, maxillary cysts, obstruction to the dental eruption and development disorders, such as palatine fissure (1). The prevalence of tooth in nasal cavity among the patients with palatine lip and fissure is of 0.48% (4). The patient in this case is not included in the statistics as for the etiology, since he was not target of trauma or any procedure that could have resulted in dental intrusion. And he did not either present an associated pathology to confirm the finding.

The tooth may emerge in the maxillary sinus, mandibular condylus, orbit, palate, through the skin and nasal cavity (5).

The tooth in nasal cavity may be asymptomatic or present with suggestive symptoms and signals of unilateral rhinosinusal process: nasal obstruction, intermittent epistaxis, recurrent infectious sinusopathy, oronasal fistula, rhinorrhea, headache and septal perforation, generally covered by granulomatous tissue (1,5). The patient had not presented any symptom relating to the tooth, and the finding was occasional. It was removed from the nasal cavity without mucous coverage.

The diagnosis is made by the clinical and radiological exam, which differ from other conditions that manifest with similar symptomatology, such as: rhinolith, foreign body, tumor (1). The images obtained by nasal video-endoscopy and computed tomography confirm a radiopaque image and draws the attention to a possible tooth. Such clarification was important both for the exclusion of potentially severe pathologies and the surgical planning, allowing a viewing of the anatomic limits.

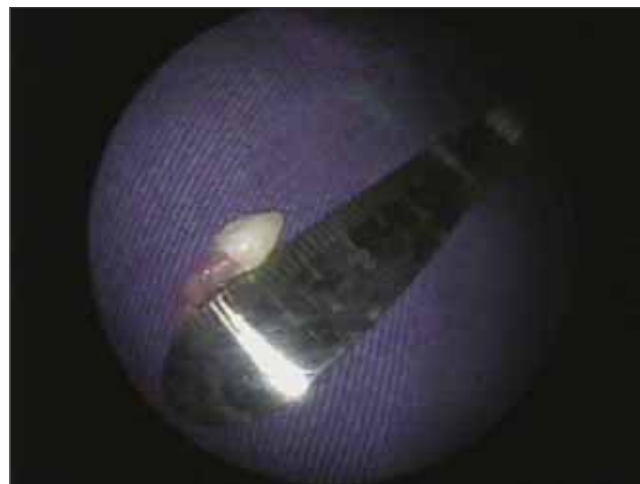The treatment comprises the entire extraction of the tooth, even in asymptomatic cases, due to the recurrence of symptoms and possible complications: abscesses, dental deformities and thrombosis of the cavernous sinus (1). The endoscopic approach is recommended for a lower level of morbidity, good lighting, viewing of adjacent structures and precise dissection (3,6). Therefore the patient was surgically treated with the help of endoscopy, which certainly contributed for the efficient exeresis and absence of postoperative problems.

---

### FINAL COMMENTS

---

Despite the uncommon ectopic presentation in nasal



**Picture 4.** Tooth after surgical extraction.

cavity, the non-traumatic etiology, common in the age range, and the asymptomatic nature makes the report even more peculiar. The treatment carried out was the endoscopic extraction with telescope of 30°, a procedure performed without abnormalities, as well as in the postoperative.

The health professionals must beware with the lack of tooth after a facial trauma for the possibility it has to accommodate in maxilla, gum, oral cavity, stomach, lung and rhinosinusal tract (3).

---

### BIBLIOGRAPHICAL REFERENCES

---

1. Moreano EH, Zich DK, Goree JC, Graham SM. Nasal tooth. *Am J Otolaryngol.* 1998, 19(2):124-6.
2. Thor AL. Delayed removal of a fully intruded primary incisor through the nasal cavity: a case report. *Dental Traumatol.* 2002, 18(4):227-30.
3. Wang LF, Tai CF, Lee KW, Ho KY, Kuo WR. Delayed removal of a fully intruded tooth in the nasal cavity after facial trauma: a case report. *Otolaryngol Head Neck Surg.* 2004, 131(3):330-1.
4. Medeiros AS, Gomide MR, Costa B, Carrara CF, das Neves LT. Prevalence of intranasal ectopic teeth in children with complete unilateral and bilateral cleft lip and palate. *Cleft Palate Craniofac J.* 2000, 37(3):271-3.
5. Lee JH. A nasal tooth associated with septal perforation: A rare occurrence. *Eur Arch Oto-rhino-laryngol.* 2006, 263(11):1055-6.
6. Kim DH, Kim JM, Chae SW, Hwang SJ, Lee SH, Lee HM. Endoscopic removal of an intranasal ectopic tooth. *Int J Pediatr Otorhinolaryngol.* 2003, 67(1):79-81.