

Hemangioma as Mass of External Ear Canal

José Faibes Lubianca Neto*, **Mauricio Schreiner Miura****, **Catia Saleh*****, **Marina de Andrade*****,
Melina Assmann***.

* PhD Degree in Medical Science by *Universidade Federal do Rio Grande do Sul*. Adjunct Professor of the ENT and Ophthalmology department of the *Fundação Federal Faculdade de Ciências Médicas de Porto Alegre*. Professor of the Post-graduation program in Medical Science at *Universidade Federal do Rio Grande do Sul*.

** PhD Student of the Post-graduation program in Medical Science at *Universidade Federal do Rio Grande do Sul*. ENT Doctor at *Complexo Hospitalar Santa Casa de Porto Alegre*.

*** Medical Student at *Fundação Federal Faculdade de Ciências Médicas de Porto Alegre*.

Institution: *Fundação Federal Faculdade de Ciências Médicas de Porto Alegre. Programa de Pós-Graduação em Ciências Médicas. Universidade Federal do Rio Grande do Sul*
Federal Institution – Medical Science College. Post-graduation Program in Medical Science.
Federal University – *Rio Grande do Sul* – Brazil.
Porto Alegre / RS – Brazil.

Address for correspondence: José Faibes Lubianca Neto – *Clínica Otorrinos Porto Alegre* (ENT Clinic) – Rua Dona Laura, 320, 9º andar – Porto Alegre / RS – Brazil
– Zip code: 90430-090 – Telephone / Fax: (+55 51) 3029-8749 – E-mail: jlubianca@terra.com.br

Article received on January 10th, 2007. Article approved on June 29th, 2007.

SUMMARY

- Introduction:** Tumoral lesions of external ear canal are uncommon findings in daily ENT practice. The possibility of hemangioma should always be remembered.
- Objective:** To report a case of a patient with hemangioma in external ear canal.
- Case Report:** Patient with a round and soft lesion completely covered with skin without modification in color fulfilling approximately 90% of external ear canal diameter. Patient's complain was dullness sensations on affected ear. CT scan demonstrated lack of tympanic membrane commitment and pathological findings were compatible with hemangioma.
- Conclusion:** It is important to define whether there is hemangioma's involvement of tympanic membrane, finding that could be determined through temporal bone CT scan. Treatment is based on surgical removal of lesion.
- Key words:** hemangioma, external ear canal, external ear, hearing loss.

INTRODUCTION

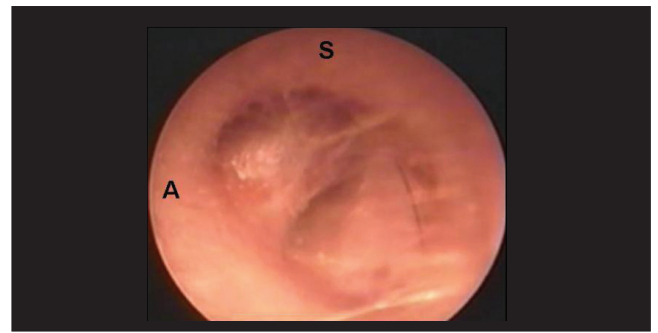
Several diseases can affect the external ear canal (EAC), causing conductive hearing loss. They are usually associated with ear pain, otorrhea and tinnitus, and the main cause is the presence of cerumen, eczema, external otitis and otomycosis. The benign tumors on this area are a rare process, but its etiological diagnosis is important (1) as the otoscopic findings do not present differences between benign and malignant lesions.

Exostosis is the most found benign tumor of the EAC (6.3 in 1000 patients with ENT complaints) (2). Vascular lesions are less common and hemangioma is the main one. The differential diagnosis is important in order to determine the correct analysis and proper therapy (3).


Hemangioma is a vascular lesion usually found in the dermis. It is more common in young children and it progressively disappears before the ages of 5-6 years. They occur in two developmental stages (1): a quick growth stage (proliferative stage), followed by a decline one. In histological terms, an endothelial hyperplasia and an increase of mastocytes is noticed in the proliferative stage. Fibrosis, fatty infiltration, cell reduction and number normalization of mastocytes are noticed in the decline stage (2). Hemangioma can be either capillary type when vessels are organized in capillary structures or cavernous type when presenting large vascular spaces, which is more common in the skin and in the mucosa. In children, during the proliferative phase, it has been observed that the urine and serum levels of the basic fibroblasts growth factor (bFGF) have increased (1).

CASE REPORT

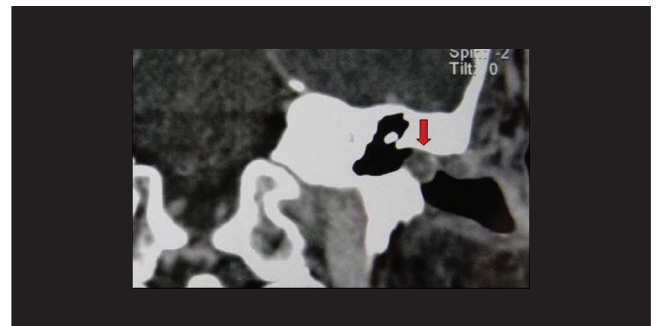A 41-year-old-male Caucasian patient searched for ENT assistance complaining of progressive hearing loss to the left for the past 2 months. He did not report ear pain, otorrhea or even previous history of otological disorder. He had previously gone to another service complaining of hearing muffling to the left, being diagnosed with Eustachian tube dysfunction disorder and treated with loratadine and pseudoefedrine, but no success. Through otoscopy, pedicled mass could be seen starting from anteroposterior wall of the internal third of the left EAC (Picture 1). The lesion virtually occupied all EAC diameters, but it was possible to compress the mass and to observe the tympanic membrane (TM). When compressing the mass, transitory auditory improved, but with the increase of the lesion, hearing ability got worse. CT scan (TC) of temporal bone was carried through, what confirmed the localization of the lesion, the absence of TM involvement and the absence of



Picture 1. Pedicled mass of the left external auditory canal (A: anterior; S: superior).



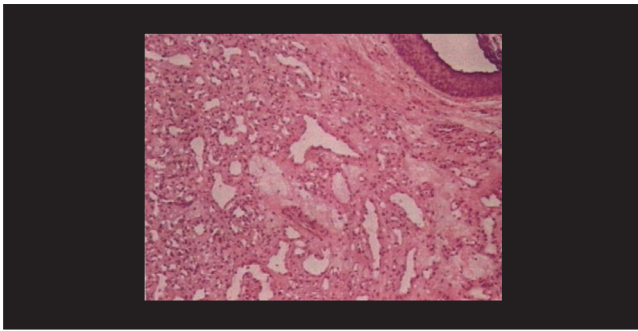
Picture 2. CT scan finds lesion (arrow), showing no involvement of the tympanic membrane and no extension to adjacent structures.



Picture 3. CT scan showing mild impregnation by contrast in the lesion surroundings (arrow).

spreading to other areas, and also mild impregnation by the contrast in the lesion surroundings (Picture 2 and 3).

Patient was submitted to transcanal surgery, by displacing EAC skin up to the lesion, when there was an intense bleeding, which was partially managed with cotton pieces soaked in vasoconstrictor and cauterization of pedicle of the lesion that transversed tympanic bone, but without eroding it. Dissection of the skin was carried out, but there was no success and then after that a medial incision to the mass in order to avoid displacement and unexpected



Picture 4. Histopathological exam showing microvascular hamangioma.

lesions in the midline skin of the EAC and of the tympanic angle. At this stage, the lesion was removed with posterior drilling, by using drill diamond burs of the anterior wall of the EAC, in order to perform a better hemostasis. The area was fulfilled with skin graft from the midline surface of the left arm. The anatomopathological diagnosed microvascular hemangioma (Picture 4). Patient condition improved and he presented with no symptoms in the last examination (6 months after surgery). He had complete cicatrization of the EAC and no recurrence of the lesion.

DISCUSSION

FREEDMAN (in 1972) was the first to report the presence of hemangioma in the outer ear, describing two male patients at their 60's with lesion that started from the posterior wall of the EAC affecting TM (4). Since then, few cases have been reported. In 1987, Hawk and van Nostrand described the first case of hemangioma of EAC with no involvement TM, and up to now there have been only 3 cases like that (1). In the current case, lesion started from the anterior wall of the ECA and when compressed, it does not seem to affect TM.

Differential diagnosis of the vascular lesions in the ear counts for: glomus jugulare and glomus tympanic tumors, high jugular bulb, aberrant internal carotid artery, arterial-venous malformations and others (1). Otoscopy revealed a non pulsatile lesion and no color alteration. Even so, temporal bone CT with contrast is important to achieve differential diagnosis, limiting the lesion extension and evaluating its vascularization (6). CT did not show TM involvement or extension to adjacent structures, besides it showed mild impregnation by contrast in the lesion surroundings.

Hemangioma treatment consists of surgery and its removal. When removing the lesion, the current authors

built a skin graft in the site due to the extension of the bloody area. Definite diagnosis is done through the anatomopathological exam (8), and prognosis is favorable most of time and its recurrence is rare (7). Patient presented with good recovery and no recurrence of the lesion.

CONCLUSION

The presence of tumor mass in the EAC can offer several diagnosis hypotheses, such as hemangioma, especially if the lesion is soft and compressible, regardless skin color, as the reported case. It is important to limit the lesion regarding localization, tympanic membrane involvement and invasion of adjacent structures, and CT scan is the best exam for that. Surgery is the best therapy for hemangiomas by providing good prognosis and few chances of complications.

REFERENCES

1. Reeck JB, Yen TL, Szmit A, Cheung SW. Cavernous hemangioma of the external ear canal. *Laryngoscope*. 2002, 112(10):1750-2.
2. Newcomer NT, Marple B. Benign Tumors of the External Ear. *Emedicine*, 2002: <http://www.emedicine.com/ent/topic706.htm>.
3. Limb CJ, Mabrie DC, Carey JP, Minor LB. Hemangioma of the external auditory canal. *Otolaryngol Head Neck Surg*. 2002, 126(1):74-5.
4. Freedman SI, Barton S, Goodhill V. Cavernous angiomas of the tympanic membrane. *Arch Otolaryngol*. 1972, 96(2):158-60.
5. Hawke M, van Nostrand P. Cavernous hemangioma of the external ear canal. *J Otolaryngol*. 1987, 16(1):40-2.
6. Chakeres DW, Kapila A, LaMasters D. Soft-tissue abnormalities of the external auditory canal: subject review of CT findings. *Radiology*. 1985, 156(1):105-9.
7. Jackson CG, Levine SC, McKennan KX. Recurrent hemangioma of the external auditory canal. *Am J Otol*. 1990, 11(2):117-8.
8. Kemink JL, Graham MD, McClatchey KD. Hemangioma of the external auditory canal. *Am J Otol*. 1983, 5(2):125-6.